

FACILITY AVAILABLE : • NON VASCULAR INTERVENTION • 16 SLICE CT SCAN • 3D & 4D SONOGRAPHY WITH COLOR DOPPLER
 • TRANS RECTAL ULTRASOUND • TRANS ANAL ULTRASOUND • FULL LEG SPINE SCANOGRAM • DIGITAL X-RAY WITH IMAGE INTENSIFIER
 • DIGITAL OPG • DIGITAL MAMOGRAPHY • SONOMAMMOGRAPHY • ELASTOGRAPHY • BMD/DEXA SCAN • ECHOCARDIOGRAPHY
 • COMPUTERISED ECG • VIDEO DIGITAL EEG • BERA • SPIROMETER • PATHOLOGY • HISTO-PATHOLOGY • CYTOLOGY

FORM 21 (Annexure)
 [prescribed under Rule(19)]
 Health Register

(in respect of persons employed in occupation declared to be dangerous operation under section 87)

PRE-EMPLOYMENT & PERIODIC MEDICAL EXAMINATION

Registration No : 030

Date : 13-12-2022

Name : PRITAM SHANDIL	Age (Years): 32	Gender : Male
Nature of Employment :	Employee No. : 303064	
Date of Joining :	Last Medical Date :	
Department : P.P. PROCESS	Designation : ENGINEER	
No. of Working Year : Previous Working :	Mobile No. :	
ESIC Number :	Aadhar No. :	

1. GENERAL EXAMINATION

HEIGHT : 167 cm	WEIGHT : 64 Kg	BMI : 22.95
CHEST INSPIRATION : 92 cm	EXPIRATION : 97 cm	BUILT : Average
THROAT : Normal	THYROID : Note Palpabel	LYMPH NODES : Note Palpabel
TOUNGE : Normal	TEETH : Normal	GUMS : Normal
TONSILS : Normal	ADDITIONAL FINDING IF ANY : Absent	

2. CARDIO-VASCULAR SYSTEM

PULSE : 75/min Regular	PERIPHERAL PULSE : Felt
BP : 140/60 mmHg	MURMUR IF ANY : Absent
HEART SOUND : Normal	ADDITIONAL FINDING IF ANY : Absent

3. RESPIRATORY SYSTEM

SHAPE OF CHEST : Normal	CHEST MOVEMENTS : Normal
TRACHEA : Normal	BREATH SOUNDS : Normal

4. GASTRO-INTESTINAL SYSTEM

LIVER : Note Palpabel	SPLEEN : Note Palpabel
ANY ABDOMINAL LUMP : Absent	

5. EXAMINATION OF EYE

EXTERNAL EXAMINATIN SQUINT : Normal	NYSTAGMUS : Normal
COLOUR VISION : Normal	FUNDUS : Normal
INDIVIDUAL COLOUR IDENTIFICATION : Normal	
DISTANT VISION (WITHOUT GLASSES)	NEAR VISION (WITHOUT GLASSES)
RIGHT : 6/6 LEFT : 6/6	RIGHT : N/6 LEFT : N/6
DISTANT VISION (WITH GLASSES)	NEAR VISION (WITH GLASSES)
RIGHT : LEFT :	RIGHT : LEFT :

6. EXAMINATION EAR, NOSE & THROAT : EXTERNAL EXAMINATION :- Normal

7. GENITO URINARY SYSTEM

HERNIA : Absent	HYDROCELE / VERICOCELE : Absent	CRYPTORCHISISM : Absent
PHIMOSIS : Absent	VARICOSE VEIN : Absent	SIGNS OF STD : Absent
OTHER EXAMINATIN FOR FEMALES : MENSTRUAL HISTORY OBSTERIC HISTORY		
MENARCHE AT : YRS :	GRAVIDA :	PARA:
LMP :	MENSTRUL IRREGULARITY IF ANY :	

RADIOLOGY

DR. RAJESH RUPRELA

MBBS, DMRE, FICA (USA), MRSH (LONDON)
 Radiologist

RADIOLOGY

DR. HARSHAD RUPRELA

MBBS, DMRD, DNB (MUMBAI)
 Radiologist



Ruprela

(SINCE 1982)

X-ray & Advanced Diagnostic Centre

(AN ISO Certified lab - certificate No. UK-RXR-0201)

OPP. TAHSIL OFFICE, BEHIND BAJRANG MANDIR

G.E. ROAD KATCHERY CHOWK, RAIPUR

TEL : 0771-2234270

M : 7470889922

E-Mail : ruprelahealthcare7@gmail.com

FACILITY AVAILABLE : • NON VASCULAR INTERVENTION • 16 SLICE CT SCAN • 3D & 4D SONOGRAPHY WITH COLOR DOPPLER
 • TRANS RECTAL ULTRASOUND • TRANS ANAL ULTRASOUND • FULL LEG SPINE SCANOGAM • DIGITAL X-RAY WITH IMAGE INTENSIFIER
 • DIGITAL OPG • DIGITAL MAMOGRAPHY • SONOMAMMOGRAPHY • ELASTOGRAPHY • BMD/DEXA SCAN • ECHOCARDIOGRAPHY
 • COMPUTERISED ECG • VIDEO DIGITAL EEG • BERA • SPIROMETER • PATHOLOGY • HISTO-PATHOLOGY • CYTOLOGY

INVESTIGATION

8. LAB INVESTIGATION :

HEMOGRAM	LIPID PROFILE	HEPATIC PROFILE
HB : 13.5 gm %	Cholesterol : 152.0 mg/dl	Bilirubin : (Total) 0.75 mg %
TLC : 9500 cmm	Tryglyceride : 139.0 mg/dl	Bilirubin (Direct) : 0.21 mg %
DLC : P 55 L 41 E 02 M 02 B 00	HDL : 57.0 mg/dl	Bilirubin (Indirect) : 0.54 mg %
RBC : 4.9 million/cmm	LDL : 67.20 mg/dl	SGOT : 19.0 IU/L
Platelet : 328 lacs/cmm	VLDL : 27.80 mg/dl	SGPT : 24.0 IU/L
ESR : 08 mm/hr	CHO:HDL :	ALK PHOS 105.0 IU/L
Blood Group : A- RH Type : Negative		
METABOLIC	OTHER INVESTIGATION	URINE EXAMINATION
B.Sugar (F) : 92.0 mg/dl	Anti HIV 1 & 2 :	Urine Albumin : Nil
B.Sugar (PP) : 113.0 mg/dl	HBsAg :	Urine Sugar : Nil
Uric Acid : 5.5 mg/dl	Anti HCV :	Microscopy : Nil
Blood Urea : 26.0 mg/dl	Syphilis :	
SR CREAT : 0.64 mg/dl	THS :	
STOOL : mg/dl	WIDAL :	

9. OTHER INVESTIGATIONS :

- ECG (In case of any abnormality further test should be carried out.) : Normal
- X ray chest (In normal person once in 3 years, in case of any abnormality X ray can be done at shorter intervals.) : Normal
- Ultrasound whole abdomen (In normal person once in 3 years, in case of any abnormality X ray can be done at shorter intervals.) : Normal
- Others :

10. PULMONARY FUNCTION TESTS :

	FVC	FEC 1	FEC1/FVC
Predicted			
Measured			
% of Predicted	130	133	102

Remarks : Normal

11. AUDIOMETRY EXAMINATION : Normal

12. MEDICAL EXAMINATION OF CANTEEN STAFF :

13. Detail of other specific medical examination carried out as mentioned in the respective in the respective schedules or rule 107 of CG factories rules 1962.

Signature (with date) of factory medical officer

Signature (with date) of certifying surgeon

DR. HARSHAD RUPRELA
 MBBS, DMRO, D.N.D.
 REG. NO.: CGMC 6249/2016

RADIOLOGY

DR. RAJESH RUPRELA

MBBS, DMRE, FICA (USA), MRSH (LONDON)
Radiologist

RADIOLOGY

DR. HARSHAD RUPRELA

MBBS, DMRD, DNB (MUMBAI)
Radiologist

FACILITY AVAILABLE : • NON VASCULAR INTERVENTION • 16 SLICE CT SCAN • 3D & 4D SONOGRAPHY WITH COLOR DOPPLER
• TRANS RECTAL ULTRASOUND • TRANS ANAL ULTRASOUND • FULL LEG SPINE SCANOGAM • DIGITAL X-RAY WITH IMAGE INTENSIFIER
• DIGITAL OPG • DIGITAL MAMOGRAPHY • SONOMAMMOGRAPHY • ELASTOGRAPHY • BMD/DEXA SCAN • ECHOCARDIOGRAPHY
• COMPUTERISED ECG • VIDEO DIGITAL EEG • BERA • SPIROMETER • PATHOLOGY • HISTO-PATHOLOGY • CYTOLOGY

Name : PRITAM SHANDIL

Report Printed ON At : 13-12-2022

Consultant : SHRI BAJRANG POWER & ISPAT LTD (TILDA)

Age / Sex : 32 Y / Male

Sample Received On/ At : 13-12-2022

Haematology

Parameter	Result	Unit	Normal Range
ABO Group	A-		
Rh Type	Negative		
Total WBC Count	9500	/cumm	4000-11000
Total RBC	4.9	10 ⁶ /μl	3.50-5.50
Haemoglobin	13.5	g/dl	12.0-16.5
Platelet Count	328	10 ³ /μl	150-450
Neutrophils	55	%	40-75
Lymphocytes	41	%	20-40
Eosinophils	02	%	1-6
Monocytes	02	%	1-10
Basophils	00	%	0-1
ESR	08	mm at 1hr	05-20

CHECKED BY



DR. SHRADDHA SAHU
MBBS.MD (Pathology)
(Pathologist)

DR. SHRADDHA SAHU
MBBS. MD. (PATHOLOGY)
REG. NO.-C.G.M.C. 6485/2016

RADIOLOGY

DR. RAJESH RUPRELA

MBBS, DMRE, FICA (USA), MRSH (LONDON)
Radiologist

RADIOLOGY

DR. HARSHAD RUPRELA

MBBS, DMRD, DNB (MUMBAI)
Radiologist

FACILITY AVAILABLE : • NON VASCULAR INTERVENTION • 16 SLICE CT SCAN • 3D & 4D SONOGRAPHY WITH COLOR DOPPLER
• TRANS RECTAL ULTRASOUND • TRANS ANAL ULTRASOUND • FULL LEG SPINE SCANOGAM • DIGITAL X-RAY WITH IMAGE INTENSIFIER
• DIGITAL OPG • DIGITAL MAMOGRAPHY • SONOMAMMOGRAPHY • ELASTOGRAPHY • BMD/DEXA SCAN • ECHOCARDIOGRAPHY
• COMPUTERISED ECG • VIDEO DIGITAL EEG • BERA • SPIROMETER • PATHOLOGY • HISTO-PATHOLOGY • CYTOLOGY

Name : PRITAM SHANDIL

Age / Sex: 32 Y / Male

Report Printed ON At : 13-12-2022


Sample Received On/ At : 13-12-2022

Consultant : SHRI BAJRANG POWER & ISPAT LTD (TILDA)

Bio Chemistry

Parameter	Result	Unit	Normal Range
Urea	26.0	mg/dl	15-45
Serum Creatinine	0.64	mg/dl	0.6-1.4
Uric Acid	5.5	mg/dl	3.6-7.0
Bilirubin - Total	0.75	mg/dl	0.1-1.2
Bilirubin - Direct	0.21	mg/dl	0-0.3
Bilirubin - (Indirect)	0.54	mg/dl	0-0.6
SGOT(AST)	19.0	U/L	0-45
SGPT(ALT)	24.0	U/L	0-45
Alkaline Phosphatase(ALP)			
Alkaline Phosphatase(ALP)	105.0	U/L	41-270
Total Cholesterol	152.0	mg/dl	150-200
Triglycerides	139.0	mg/dl	35-170
HDL Cholesterol	57.0	mg/dl	35-70
VLD Cholesterol	67.20	mg/dl	Less than 100
LDL Cholesterol	27.80	mg/dl	7-35
Blood Sugar Fasting	92.0	mg/dl	70-110
Blood Sugar	113.0	mg/dl	80-140

CHECKED BY


DR. SHRADDHA SAHU
MBBS.MD (Pathology)
(Pathologist)

DR. SHRADDHA SAHU
MBBS. MD. (PATHOLOGY)
REG. NO.-C.G.M.C. 6485/2016

RADIOLOGY

DR. RAJESH RUPRELA

MBBS, DMRE, FICA (USA), MRSH (LONDON)
Radiologist

RADIOLOGY

DR. HARSHAD RUPRELA

MBBS, DMRD, DNB (MUMBAI)
Radiologist

FACILITY AVAILABLE : • NON VASCULAR INTERVENTION • 16 SLICE CT SCAN • 3D & 4D SONOGRAPHY WITH COLOR DOPPLER
 • TRANS RECTAL ULTRASOUND • TRANS ANAL ULTRASOUND • FULL LEG SPINE SCANOGRAM • DIGITAL X-RAY WITH IMAGE INTENSIFIER
 • DIGITAL OPG • DIGITAL MAMOGRAPHY • SONOMAMMOGRAPHY • ELASTOGRAPHY • BMD/DEXA SCAN • ECHOCARDIOGRAPHY
 • COMPUTERISED ECG • VIDEO DIGITAL EEG • BERA • SPIROMETER • PATHOLOGY • HISTO-PATHOLOGY • CYTOLOGY

Name : PRITAM SHANDIL

Report Printed ON At : 13-12-2022

Consultant : SHRI BAJRANG POWER & ISPAT LTD (TILDA)


Age / Sex: 32 Y / Male

Sample Received On/ At : 13-12-2022

CLINICAL PATHOLOGY

Parameter	Result	Unit	Normal Range
URINE ROUTINE ANI			
Physical Examination			
Colour	Pale Yellow		
Quantity	30	ml	>30
Appearance	Clear	-	Clear
Reaction	Acidic	-	Acidic
Chemical Examination			
Albumin	Nil	-	NIL
Sugar	Nil	%	NIL
Microscopy Examination			
RBC	Nil	/hpf	NIL
PUS Cells	2-4	/hpf	< 5
Epithelial Cells	1-2	/hpf	< 3
Crystals	Absent	-	Absent
Casts	Absent	-	Absent
Bacteria	Absent	-	Absent
Other (Urine)			

CHECKED BY


 DR. SHRADDHA SAHU
 MBBS.MD (Pathology)
 (Pathologist)

DR. SHRADDHA SAHU
 MBBS. MD. (PATHOLOGY)
 REG. NO.-C.G.M.C. 6485/2016

RADIOLOGY

DR. RAJESH RUPRELA

MBBS, DMRE, FICA (USA), MRSH (LONDON)
 Radiologist

RADIOLOGY

DR. HARSHAD RUPRELA

MBBS, DMRD, DNB (MUMBAI)
 Radiologist



Ruprela

(SINCE 1982)

X-ray & Advanced Diagnostic Centre

(AN ISO Certified lab - certificate No. UK-RXR-0201)

OPP. TAHSIL OFFICE, BEHIND BAJRANG MANDIR

G.E. ROAD KATCHERY CHOWK, RAIPUR

TEL : 0771-2234270

M : 7470889922

E-Mail : ruprelahealthcare7@gmail.com

FACILITY AVAILABLE : • NON VASCULAR INTERVENTION • 16 SLICE CT SCAN • 3D & 4D SONOGRAPHY WITH COLOR DOPPLER
• TRANS RECTAL ULTRASOUND • TRANS ANAL ULTRASOUND • FULL LEG SPINE SCANOGRAM • DIGITAL X-RAY WITH IMAGE INTENSIFIER
• DIGITAL OPG • DIGITAL MAMOGRAPHY • SONOMAMMOGRAPHY • ELASTOGRAPHY • BMD/DEXA SCAN • ECHOCARDIOGRAPHY
• COMPUTERISED ECG • VIDEO DIGITAL EEG • BERA • SPIROMETER • PATHOLOGY • HISTO-PATHOLOGY • CYTOLOGY

Name : PRITAM SHANDIL

Age / Sex: 32 Y / Male

Report Printed ON At : 13-12-2022

Sample Received On/ At : 13-12-2022

Consultant : SHRI BAJRANG POWER & ISPAT LTD (TILDA)

EYE EXAMINATION

External Exam : Normal

Squint : Normal

Nystagmus : Normal

Colour Vision -

Fundus - (L): Normal (R): Normal

Individual Colour Identification : Normal

Distant Vision (without Glass)

Right : 6/6 Left : 6/6

(With Glass) Right : Left :

Near Vision (Without Glass)

Right : N/6 Left : N/6

(With Glass) Right : Left :

Night Blindness(Nyctalopia) : Normal


DR. EKTA BATAVIA JAIN
MBBS, DNB (OPHTHALMOLOGY) FVR

RADIOLOGY

DR. RAJESH RUPRELA

MBBS, DMRE, FICA (USA), MRSH (LONDON)
Radiologist

RADIOLOGY

DR. HARSHAD RUPRELA

MBBS, DMRD, DNB (MUMBAI)
Radiologist



Ruprela

(SINCE 1982)

X-ray & Advanced Diagnostic Centre

(AN ISO Certified lab - certificate No. UK-RXR-0201)

OPP. TAHSIL OFFICE, BEHIND BAJRANG MANDIR

G.E. ROAD KATCHERY CHOWK, RAIPUR

TEL : 0771-2234270

M : 7470889922

E-Mail : ruprelahealthcare7@gmail.com

FACILITY AVAILABLE : • NON VASCULAR INTERVENTION • 16 SLICE CT SCAN • 3D & 4D SONOGRAPHY WITH COLOR DOPPLER
 • TRANS RECTAL ULTRASOUND • TRANS ANAL ULTRASOUND • FULL LEG SPINE SCANOGAM • DIGITAL X-RAY WITH IMAGE INTENSIFIER
 • DIGITAL OPG • DIGITAL MAMOGRAPHY • SONOMAMMOGRAPHY • ELASTOGRAPHY • BMD/DEXA SCAN • ECHOCARDIOGRAPHY
 • COMPUTERISED ECG • VIDEO DIGITAL EEG • BERA • SPIROMETER • PATHOLOGY • HISTO-PATHOLOGY • CYTOLOGY

Name : PRITAM SHANDIL

Age / Sex: 32 Y / Male

Report Printed ON At : 13-12-2022

Sample Received On/ At : 13-12-2022

Consultant : SHRI BAJRANG POWER & ISPAT LTD (TILDA)

X-RAY CHEST (PA) VIEW

OBSERVATION

- Both hilar shadows appear normal.
- Both lung fields are clear.
- Both costo phrenic angles are normal.
- Cardiothoracic ration is within normal limits.
- Trachea centrally placed.
- Soft tissue and bony cage appear normal.
- Both Hemidiaphragms are well outlined.

IMPRESSION

- Normal Study.

Suggest : Clinical Correlation.

DR. RAJESH RUPRELA
 MBBS,DMRE,FICA(USA), MRSH(London)

DR. HARSHAD RUPRELA
 MBBS DMRD DNB (Mumbai)
DR. HARSHAD RUPRELA
 MBBS, DMRO, D.N.B.
 REG. NO.:CGMC 6849/2016

RADIOLOGY

DR. RAJESH RUPRELA

MBBS, DMRE, FICA (USA), MRSH (LONDON)
Radiologist

RADIOLOGY

DR. HARSHAD RUPRELA

MBBS, DMRD, DNB (MUMBAI)
Radiologist



Ruprela

(SINCE 1982)

X-ray & Advanced Diagnostic Centre

(AN ISO Certified lab - certificate No. UK-RXR-0201)

OPP. TAHSIL OFFICE, BEHIND BAJRANG MANDIR

G.E. ROAD KATCHERY CHOWK, RAIPUR

TEL : 0771-2234270

M : 7470889922

E-Mail : ruprelahealthcare7@gmail.com

FACILITY AVAILABLE : • NON VASCULAR INTERVENTION • 16 SLICE CT SCAN • 3D & 4D SONOGRAPHY WITH COLOR DOPPLER
• TRANS RECTAL ULTRASOUND • TRANS ANAL ULTRASOUND • FULL LEG SPINE SCANOGAM • DIGITAL X-RAY WITH IMAGE INTENSIFIER
• DIGITAL OPG • DIGITAL MAMOGRAPHY • SONOMAMMOGRAPHY • ELASTOGRAPHY • BMD/DEXA SCAN • ECHOCARDIOGRAPHY
• COMPUTERISED ECG • VIDEO DIGITAL EEG • BERA • SPIROMETER • PATHOLOGY • HISTO-PATHOLOGY • CYTOLOGY

NAME – PRITAM SHANDIL	AGE – 32
REF BY – SHREE BAJRANG TILDA	DATE – 09.01.2023

USG ABDOMEN AND PELVIS

LIVER

: Normal in size, shape & echotexture.
No focal or diffuse lesion seen.
IHBRs & CBD are normal in appearance.
Portal vein is normal in size, hepatopetal flow.

GALL BLADDER

: Lumen is well distended & echofree. No calculus or sludge is seen.

SPLEEN

: Normal in size, shape & echotexture.
No focal lesion seen. splenic vein - normal.

RETROPERITONEUM

: Pancreas normal in size and echotexture.
No retroperitoneal / paraaortic lymphadenopathy.
Aorta and IVC normal.

KIDNEYS

: Both kidneys appear normal in size, shape & echotexture.
Cortical thickness & corticomedullary differentiation normal.
No calculus and no hydronephrosis.

PROSTATE

: Prostate is normal in size.
No median lobe bulge. echotexture normal.
No focal lesion seen. capsule is intact.

URINARY BLADDER


: Shows normal uniform wall thickness with smooth inner margin.

IMPRESSION :

NO SONOGRAPHIC ABNORMALITY DETECTED IN CURRENT SCAN.

Suggest- Clinical Correlation.

Dr. Rajesh Ruprela
MBBS, DMRE, FICA (USA), MRSH (London)


Dr. Harshad Ruprela
MBBS, DMRD, DNB (Mumbai)
DR. HARSHAD RUPRELA
MBBS, DMRO, D.N.B.
REG. NO.: CGMC 6849/2016

RADIOLOGY

DR. RAJESH RUPRELA
MBBS, DMRE, FICA (USA), MRSH (LONDON)
Radiologist

RADIOLOGY

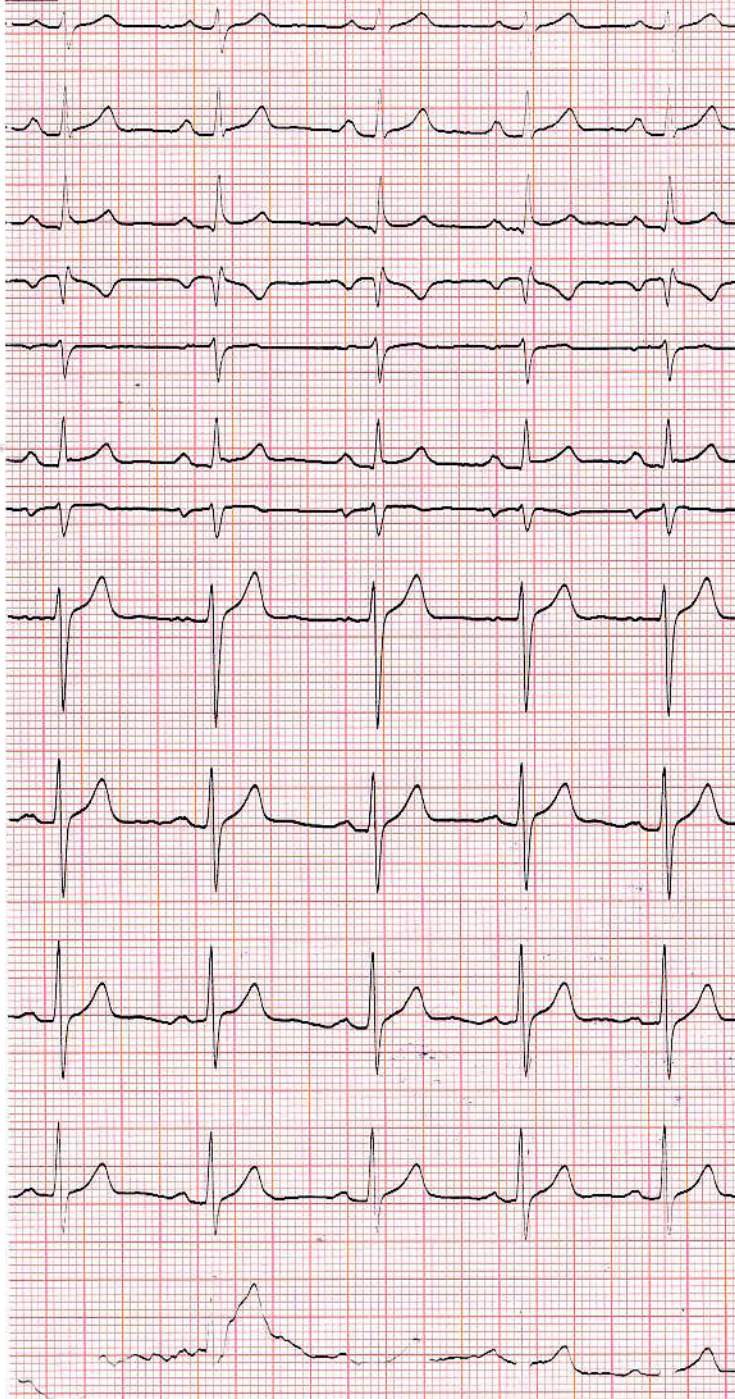
DR. HARSHAD RUPRELA
MBBS, DMRD, DNB (MUMBAI)
Radiologist

2022-12-13 17:27:57

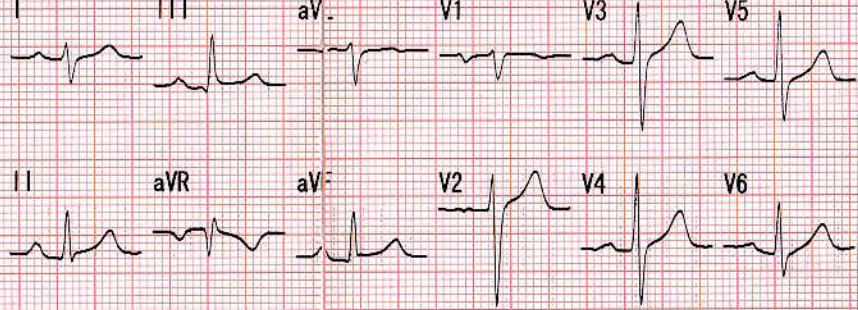
Name : PRITAM
Sex : Male Age: 2
Section : SHRI BAJR/NG POW
RoomID :
BedID :
AccessionNumber :
Operator :

HR [bpm] : 77
PQd [ms] : 189
Pd [ms] : 116
QRSd [ms] : 76
Td [ms] : 165
QT/QTc/QTcF [ms] : 323/366/350
PAx/QRSAx/TAx [deg] : 66.3/100.1/60.0
R(V5)/S(V1) [mV] : 0.94/0.32
R(V5)+S(V1) [mV] : 1.25

38



10 mm/mV 25 mm/s



<< Conclusions >>
Longitudinal Right axis deviation;
Normal Sinus Rhythm;

Report need physician confirm
physician

Dr. Gaurav Tripathi
Dr. GAURAV TRIPATHI
M.B.B.S., D.M. (Cardiology)
Reg. No. CGRI/0638/2021

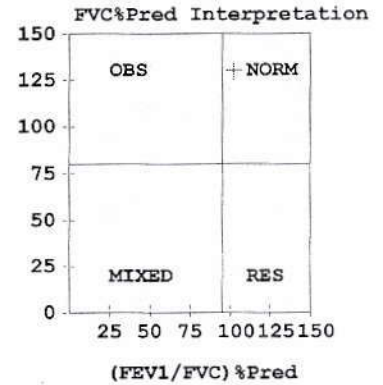
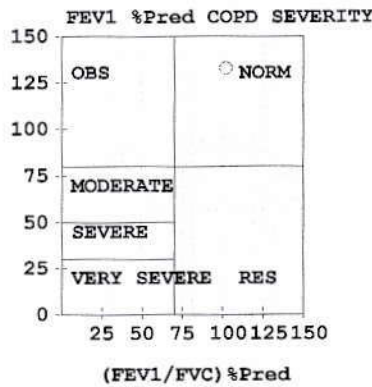
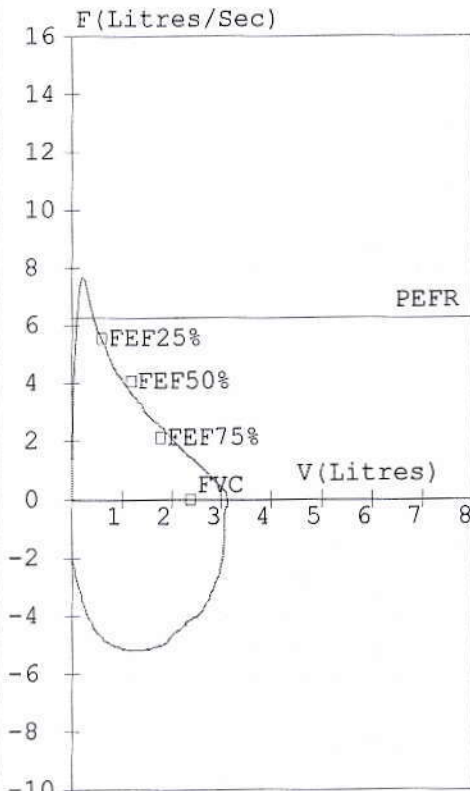
RUPRELA DIAGNOSTIC CENTER RAIPUR.

RAIPUR

Patient: PRITAM SHANDIL
 Refd. By: BAJARANG TMT
 Pred. Eqns: RECORDERS
 Date : 13-Dec-2022 05:26 PM

Age : 32 Yrs
 Height : 167 Cms
 Weight : 64 Kgs
 ID : 112549962

Gender : Male
 Smoker : No
 Eth. Corr: 70
 Temp :

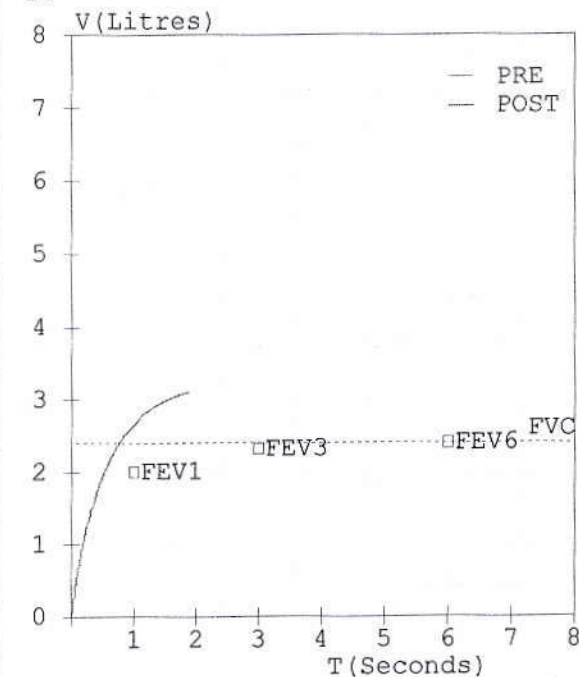


FVC Results

Parameter	Pred	M.Pre	%Pred	M.Post	%Pred	%Imp
FVC	(L) 02.39	03.11	130	-----	----	---
FEV1	(L) 02.01	02.68	133	-----	----	---
FEV1/FVC	(%) 84.10	86.17	102	-----	----	---
FEF25-75	(L/s) 02.97	02.63	089	-----	----	---
PEFR	(L/s) 06.24	07.62	122	-----	----	---
FIVC	(L) -----	03.33	----	-----	----	---
FEV.5	(L) -----	01.96	----	-----	----	---
FEV3	(L) 02.32	03.11	134	-----	----	---
PIFR	(L/s) -----	05.15	----	-----	----	---
FEF75-85	(L/s) -----	01.19	----	-----	----	---
FEF.2-1.2	(L/s) 05.10	04.94	097	-----	----	---
FEF 25%	(L/s) 05.55	04.73	085	-----	----	---
FEF 50%	(L/s) 04.05	02.81	069	-----	----	---
FEF 75%	(L/s) 02.10	01.50	071	-----	----	---
FEV.5/FVC	(%) -----	63.02	----	-----	----	---
FEV3/FVC	(%) 97.07	100.00	103	-----	----	---
FET	(Sec) -----	01.87	----	-----	----	---
ExplTime	(Sec) -----	00.03	----	-----	----	---
Lung Age	(Yrs) 032	021	066	-----	----	---
FEV6	(L) 02.39	-----	----	-----	----	---
FIF25%	(L/s) -----	04.52	----	-----	----	---
FIF50%	(L/s) -----	05.12	----	-----	----	---
FIF75%	(L/s) -----	04.22	----	-----	----	---

Pre Test COPD Severity

Test within normal limits



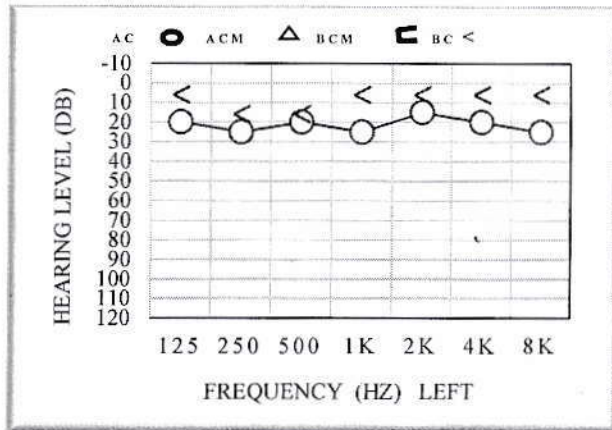
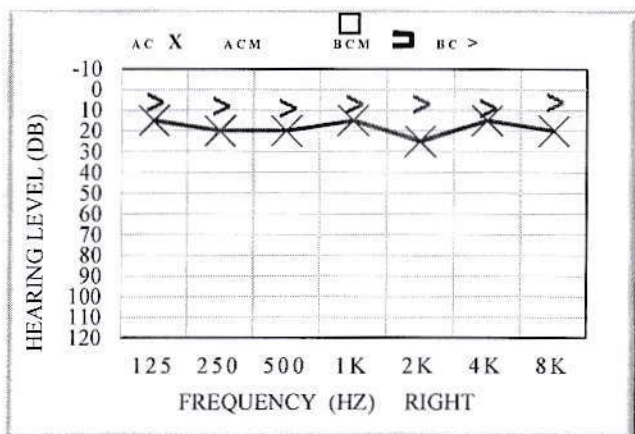
BB
Dr. B. B. KUMAR
 MBBS, MD. (Medicine)
 Reg. No. WB 52411

Pre Medication Report Indicates
 Spirometry within normal limits as (FEV1/FVC)%Pred >95 and FVC%Pred >80

RUPRELA DIAGNOSTIC CENTER RAIPUR.

COME. SHREE BAJRANG TMT
 RD NO 30
 NAAME PRITAM SHANDIL
 AGE : 32/M
 DATE : 13/12/2022

AUDIOGRAM



EAR	MODE	AIR CONDUCTION		BONE CONDUCTION		COLOUR CODE	THRESHOLD IN dB		
		MASKED	UNMASKED	MASKED	UNMASKED		AIR CONDUCTION	RIGHT	LEFT
LEFT		□	*	☐	>	BLUE	BONE CONDUCTION	17	19
RIGHT		△	○	☐	<	RED	SPEECH		

NO RESPONSE : ADD ↓BELOW THE RESPECTIVE SYMBOLS

REMARK : NORMAL HEARING IN BOTH EARS

Dr. Gaurav Ahluwalia
 Dr. Gaurav Ahluwalia
 MBBS, DNB (ENT), FRCS
 Fellowship in FESS, ACLS
 Reg. No. CGMC 2228/2009